linsen centrum

Theorie II

AS-OCT & Kontaktlinsen

linsen centrum

Artefakte mit Kontaktlinsen

Normale Artefakte OCT

linsen centrum

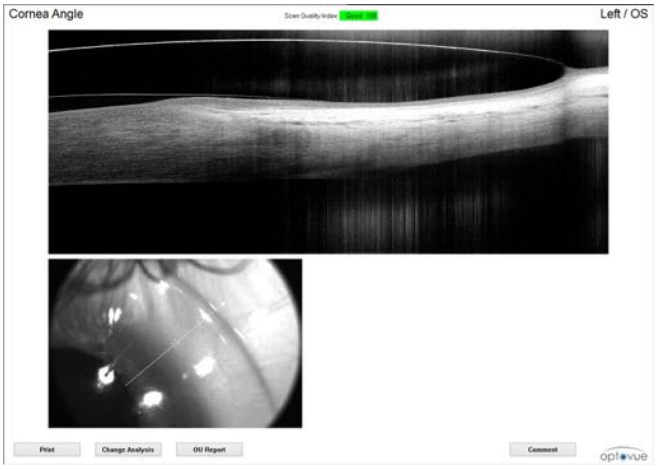

Eindrücken der Sklera?

Normale Artefakte OCT

linsen centrum

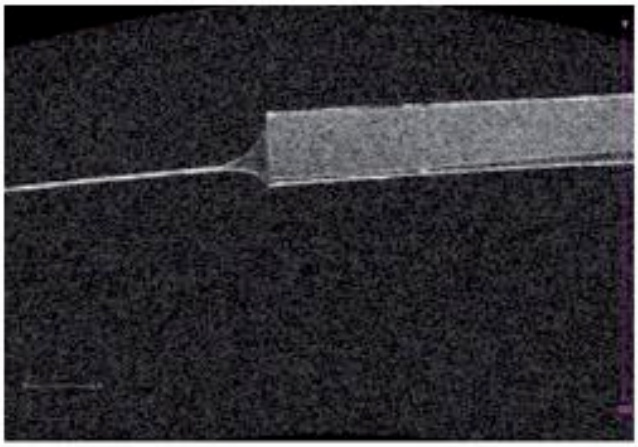

Kontaktlinsenrohmaterial auf einer mit NaCl benetzten Glasplatte

Bandlitz und Pult: Die Interpretation von OCT-Aufnahmen in der Kontaktlinsenanpassung, DOZ

Normale Artefakte OCT

linsen centrum

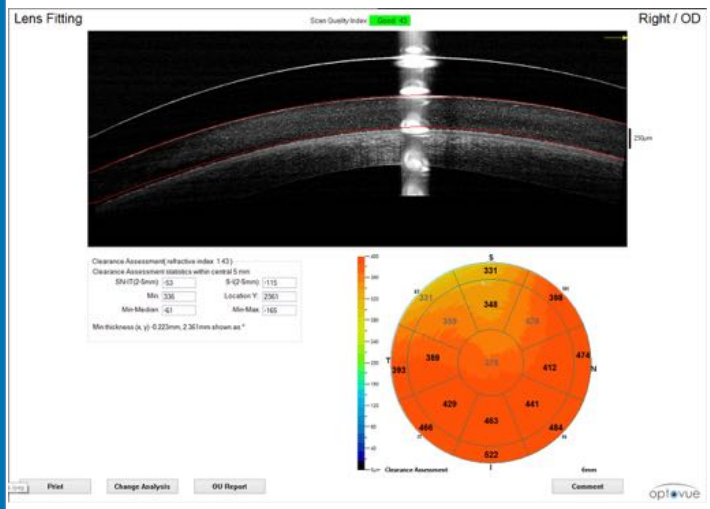

Debris unter der Sklerallinse

Normale Artefakte OCT

linsen centrum

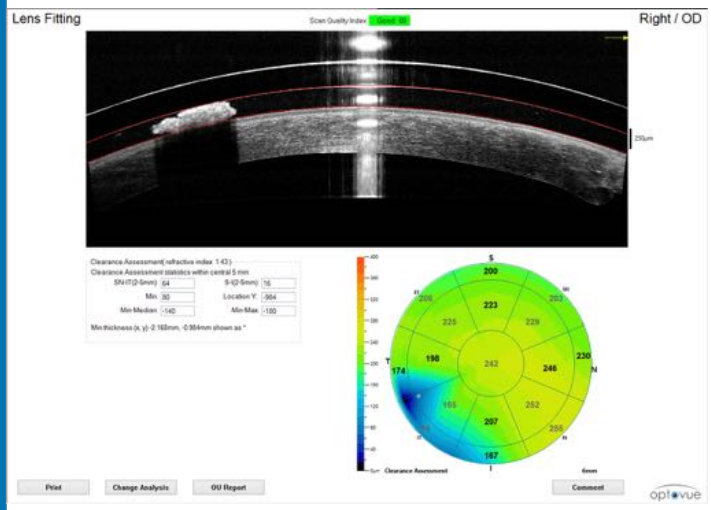

Debris, Schmutz

Artefakte OCT

linsen centrum

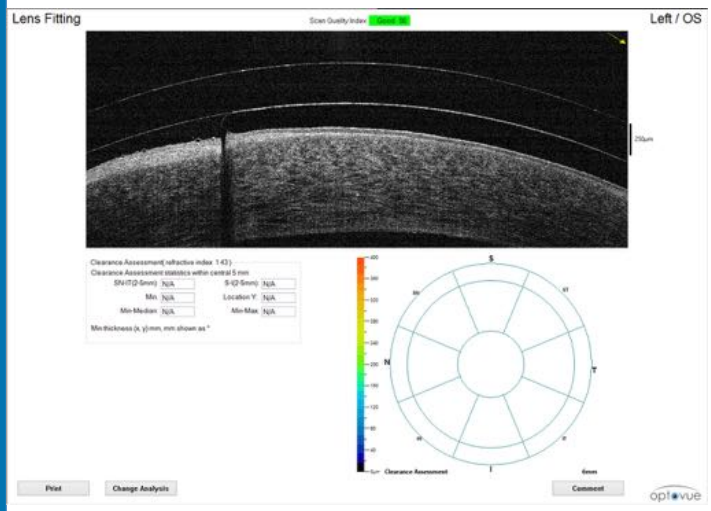

Luftblase

linsen centrum

AS-OCT für die Sklerallinsen Anpassung

AS-OCT für Kontaktlinsen

linsen centrum

- Hauptanwendung von AS-OCT für die Sklerallinsen Anpassung

- Ortho-K
- Corneoskleral Linsen
- Hybrid Linsen

AS-OCT für Skleral Linsen

linsen centrum

- Zentral
  - Pachymetrie Cornea
    - Vor und nach der Anpassung
    - Veränderungen Stroma/ Epithel
    - Ödem durch Linsentragen?

AS-OCT für Skleral Linsen

linsen centrum

- Zentral
  - Überbrückung von ScCl beurteilen
    - Apex Clearance
    - Transplantat Ränder
- OCT vs. SL
  - ScCl mit geringere Überbrückungen können angepasst werden
  - <50um kann an SL nicht mehr beurteilt werden
    - Limbus, Apex, TP-Rand

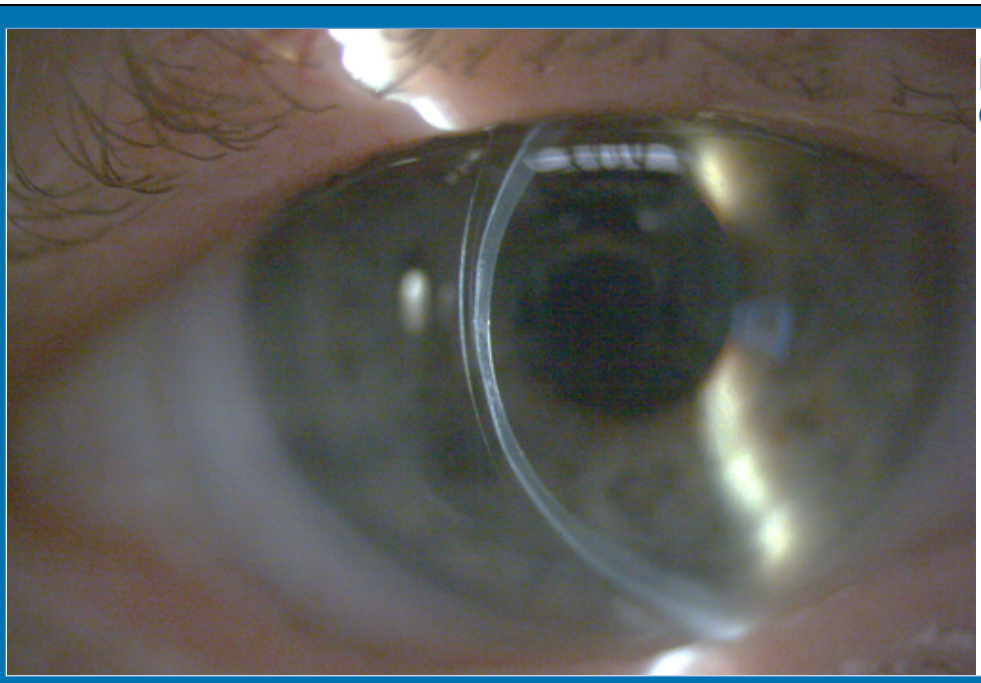

linsen centrum

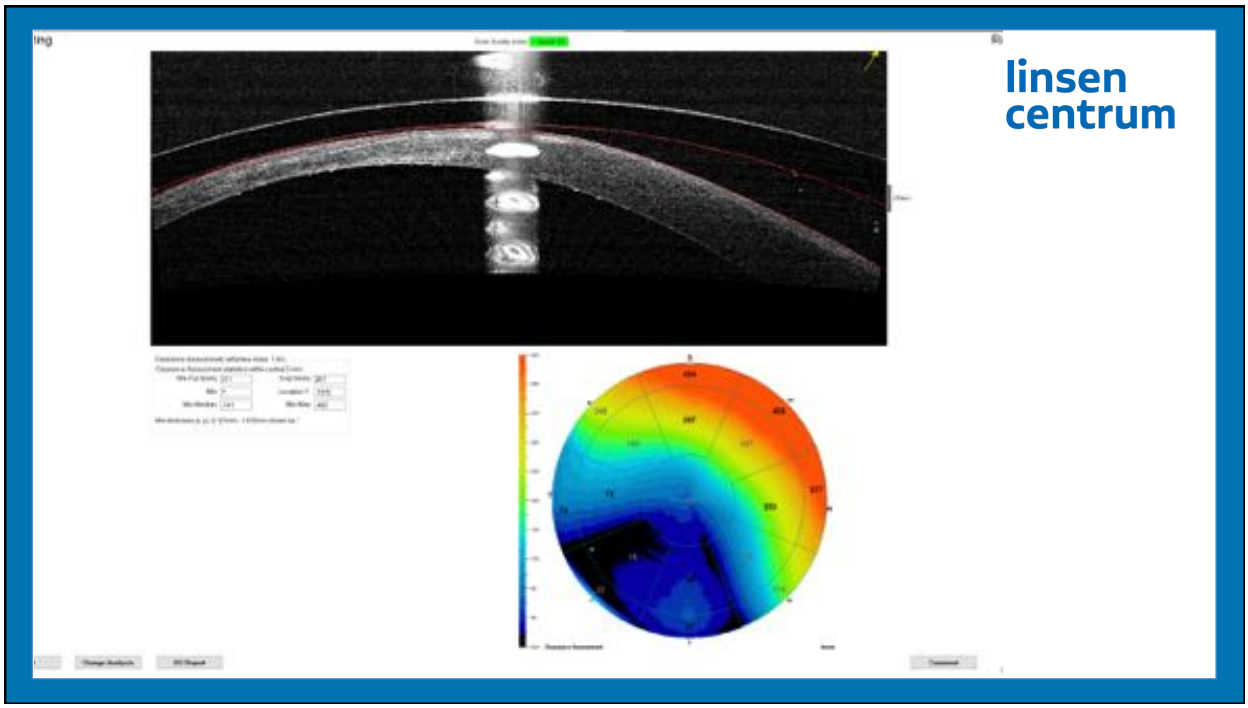

AS-OCT für Skleral Linsen

linsen
centrum

- Peripher
  - Limbale Beurteilung «Winkel» Limbalzone
    - Im flachen und steilen Hauptschnitt
  - «Durchmesser Landing-Zone» bestimmen standard, </>?
  - Skleralzone im flachen und steilen HS bestimmen

AS-OCT für Skleral Linsen

linsen centrum

- Voraussetzung ist eine gute Spaltlampen-Beurteilung der ScCl
  - Linse immer mit Fluoreszein aufsetzen
  - Zentrierung, Stabilisation, Überbrückung zentral und Limbal, Sklerallauflage
  - Wenn eine rot. symmetrische Linse am Auge ist:
    - Gibt es einen «flacher und steiler HS» in der Skleralauflage?
    - Wie ist das Überbrückungsmuster Limbal hor. vs. vert.?
    - Kann die erwartetet Stabilisation mit einer Torischen Linse verifiziert werden?
- Erst wenn eine passende Linse am Auge ist, folgt die OCT Beurteilung
  - OCT sind nur kleine Ausschnitte und zeigt keine Gesamtübersicht

Anwendung OCT

linsen centrum

- Skleralzone & Limbalzone in 4 Quadranten
  - Möglichst paralleler Scan zu Stab. Achse und CL-Oberfläche
  - In Live-View Sitz beobachten
  - Sinnvoller Ausschnitt wählen um Skleral-, Limbalzone und Ø-Skleralzone beurteilen zu können
- Achtung: OCT ist eine optisch bildgebendes Verfahren und Linse hat unterschiedlicher Brechungsindex als Luft und Reservoir
- Bei Blick nach oben und unten verschiebt sich die Linse leicht, vor allem nach frischem Einsetzen

Sklerallinsen Update

linsen centrum

- **Central Clearance:**
  - Ziel 150 bis ca. 200 μm Überbrückung für maximale O_2-Versorgung
  - NaCl Ampullen nicht immer gleich gut verträglich (Puffer)
    - Avizor, Drop & See MD, Isosol, CleaDew SL, Futuro Saline, Polyrinse
- **Limbal Clearance:**
  - Limbal paralleler Übergang entscheidend mit minimal Überbrückung verhindert Midday-Fogging
- **Scleral alignment:**
  - Sklerale Auflage mit richtigem Radius/Tangente für die optimale Druckverteilung
- **Scleral Toricity:**
  - mittlerweile 80-90% aller Sklerallinsen-Träger mit leichtem Skleral-Torus von 100-250 μm

Vault-Mapping

linsen centrum

- Clearance unter Berücksichtigung von Brechungsindex
  - Minimal kann am Ende des Tags 40-50µm betragen
  - Durchschnitt 150-200µm
- Zentrale Überbrückung beurteilen
  - Nach Linsen einsetzen
  - Nach 2-3 Std. Linsen tragen → Einsinken der CL in Konjunktiva
  - Neu vs. vorgängige Linse

Change Analysis Überbrückung

linsen centrum

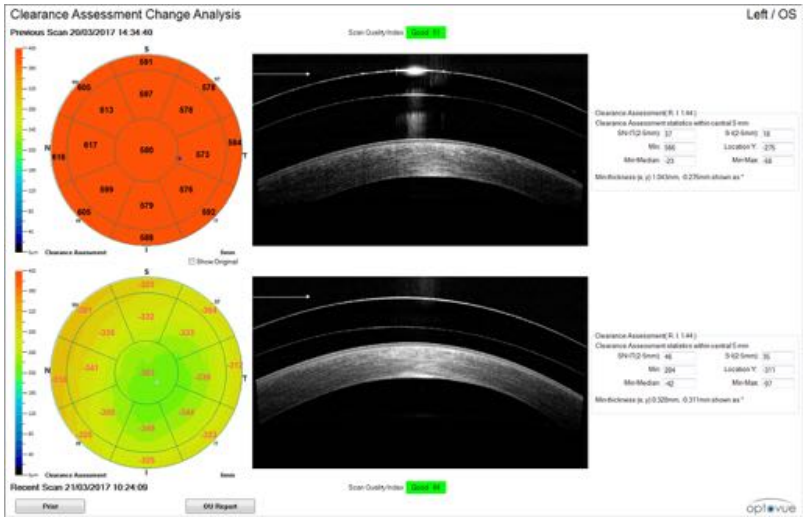

1. Messlinse vs.
2. Messlinse

Zentrale Überbrückung

linsen centrum

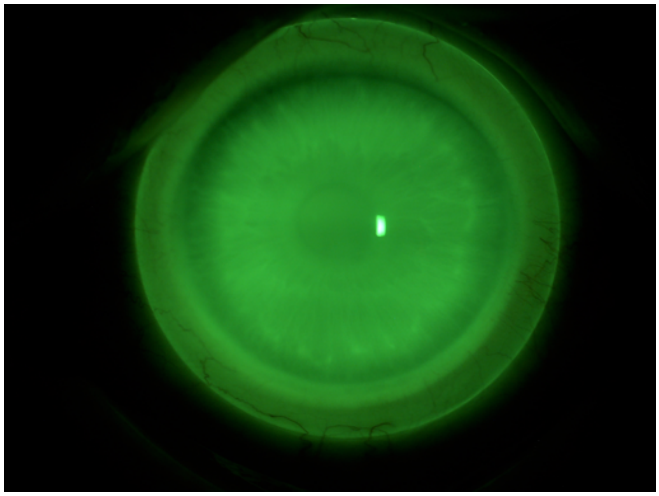

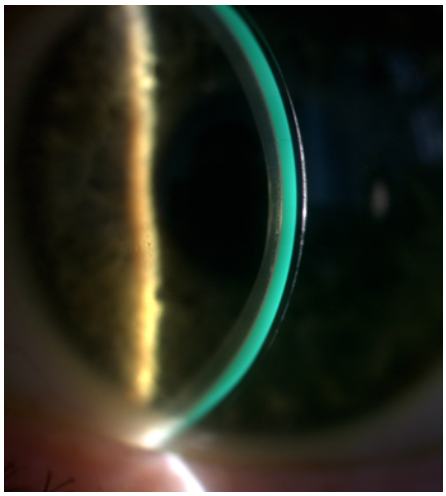

Minimal Clearance

linsen centrum

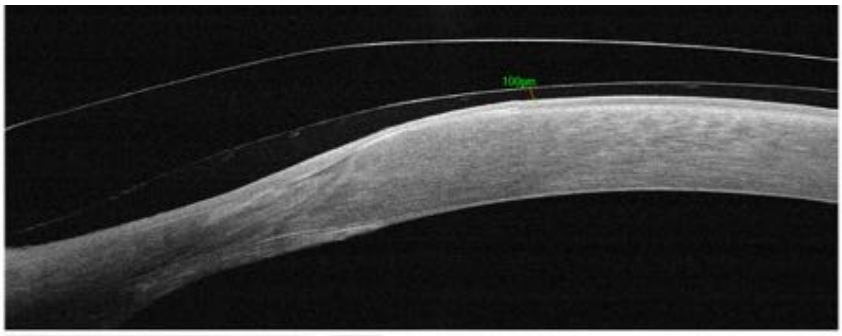

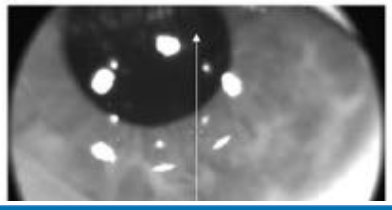

Minimal Clearance

linsen centrum

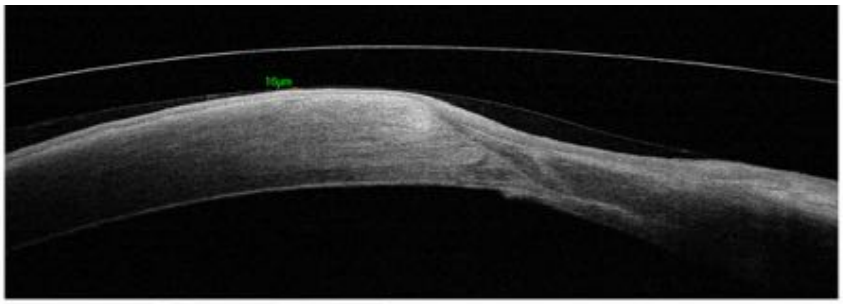

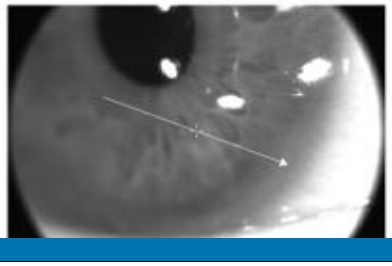

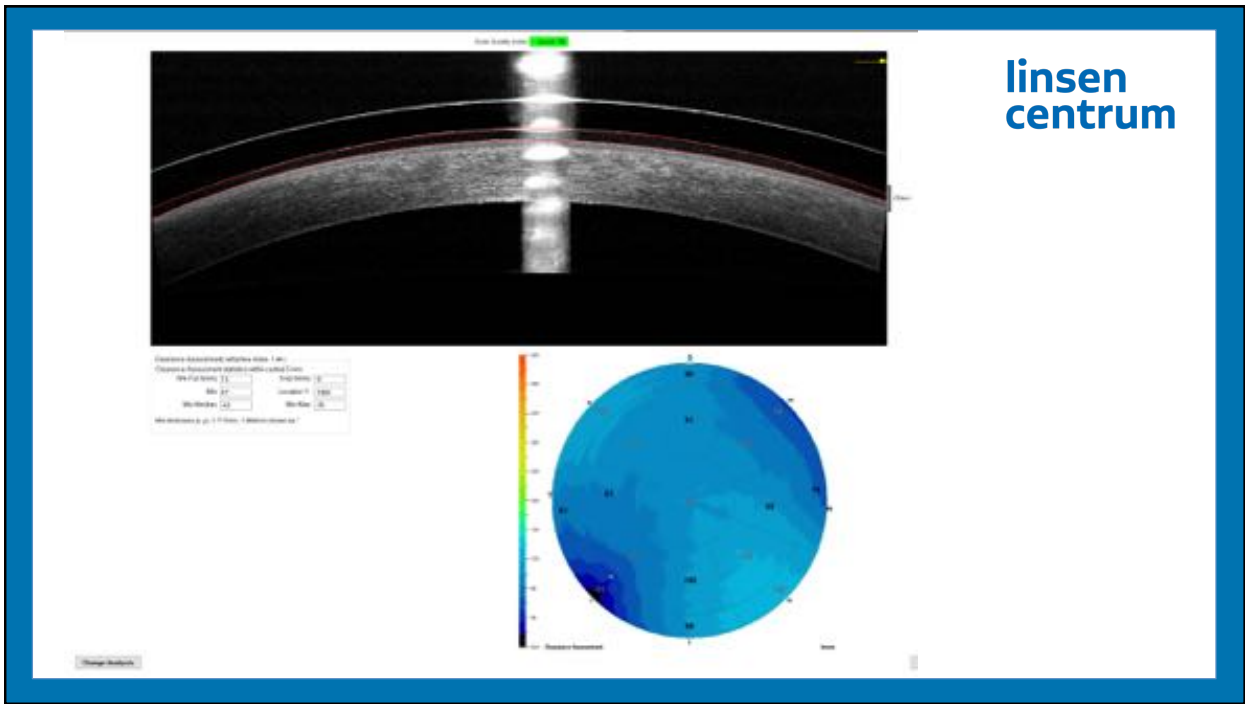
linsen
centrum

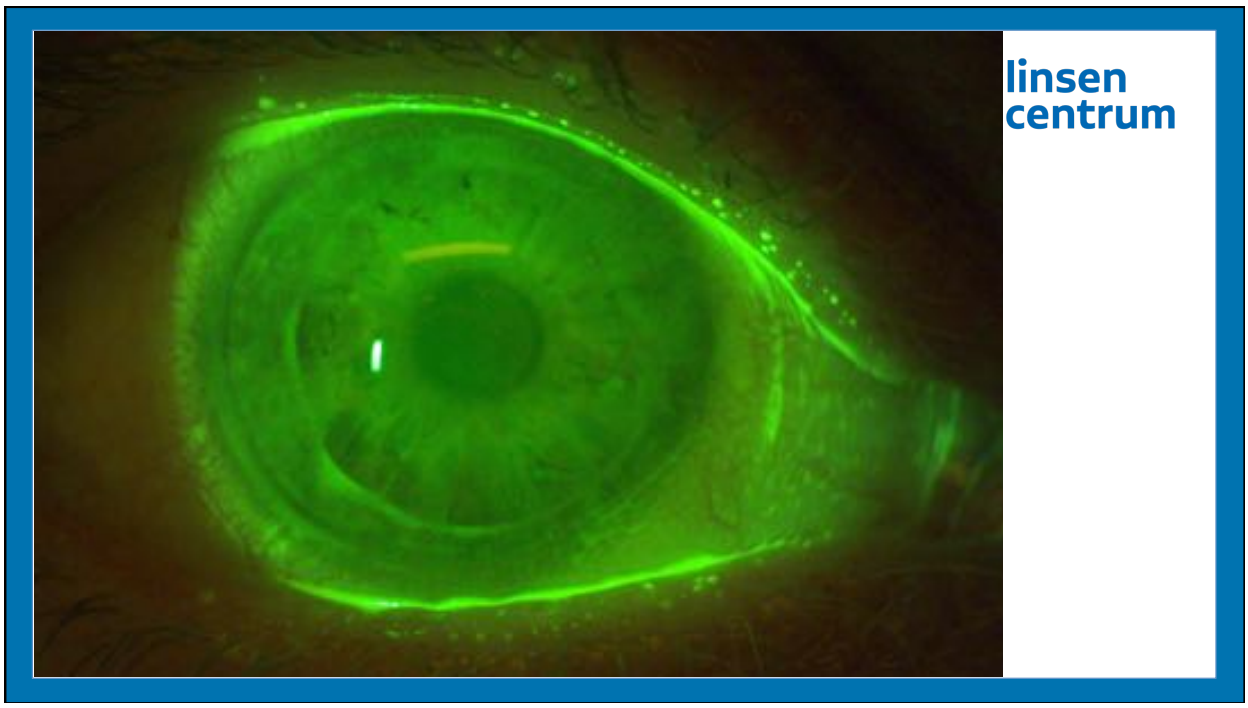
linsen
centrum

Minimal Clearance Keratokonus

linsen centrum

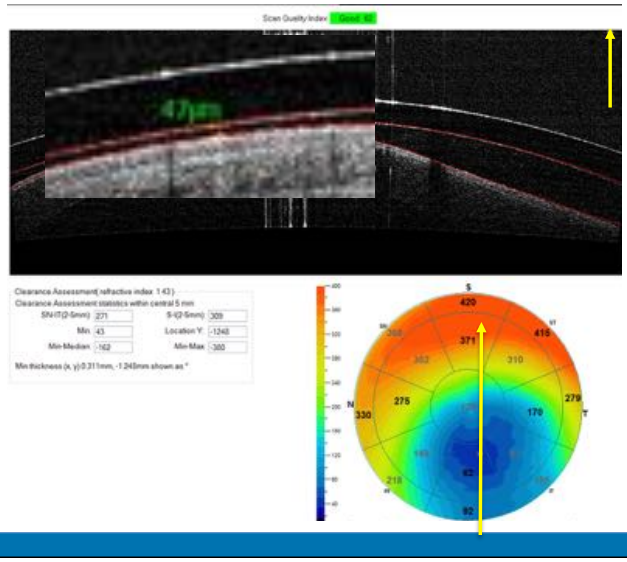

- Clearance am Apex nach 2-3 Wochen sicherstellen
- So wenig wie nötig am Apex (Mittelperipherie)
- 2. Tageshälfte min 30-50 μ
- Vorsicht nach flach angepassten RGP-Linsen !

PMD

linsen centrum

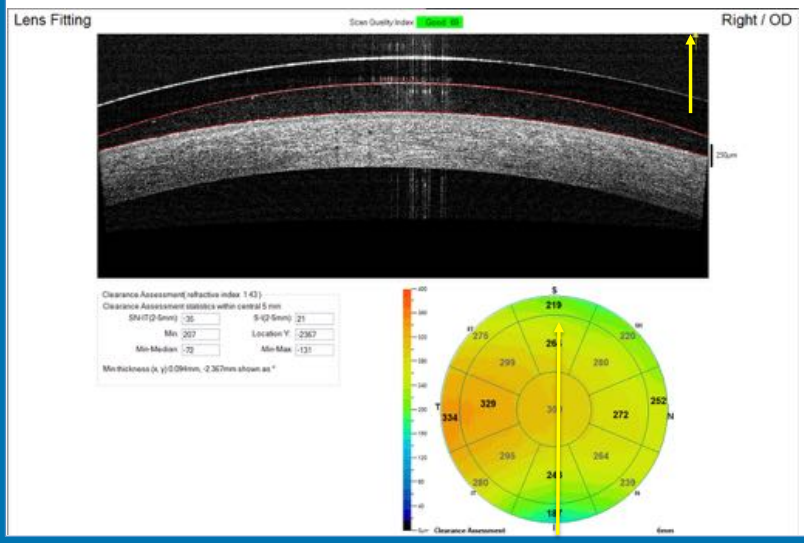

PMD

linsen centrum

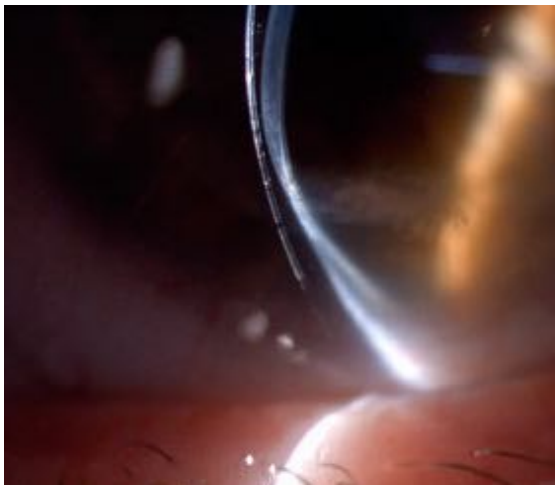

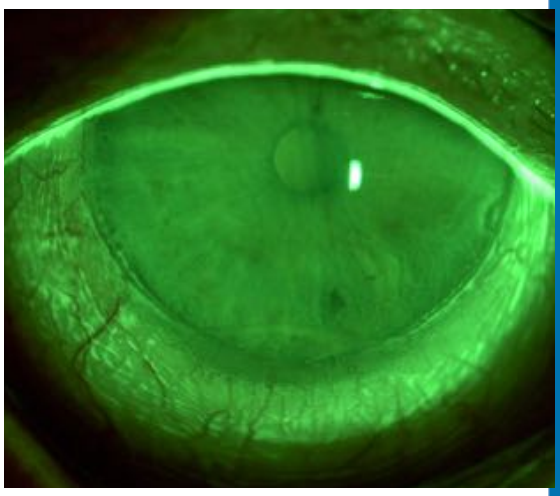

PMD

linsen centrum

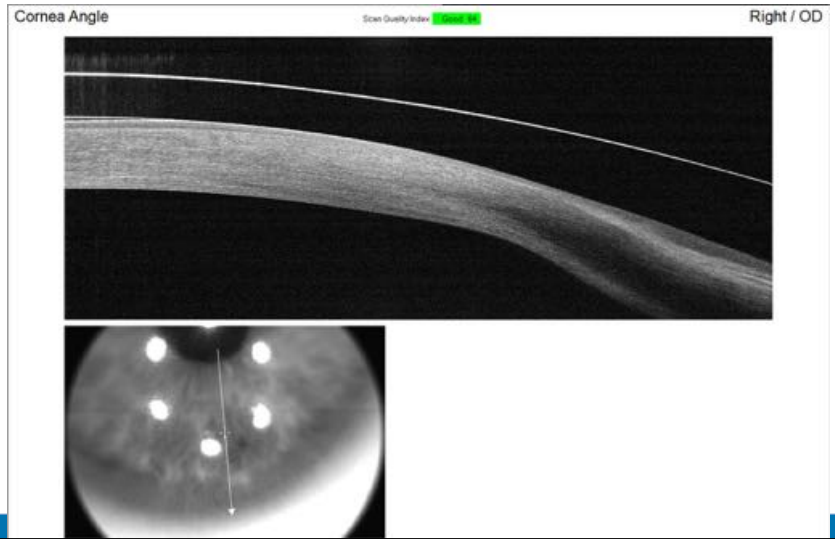

Limbal- & Skleral-Zone

linsen centrum

- Unterschiedliche Strategien von den verschiedenen Hersteller
  - Daher keine Anpass-Schulung
- Mehr gegenüber weniger Limbal Clearance
- Skleralzone und Edge-Lift
- Beginn der Landingzone im Verhältnis zum Limbus
- Torizität: Skleral-Torus vs. Limbal & Skleral-Torus

2 Linsen von verschiedene Hersteller:
gleiches Auge, gleicher Tag direkt nach einsetzen

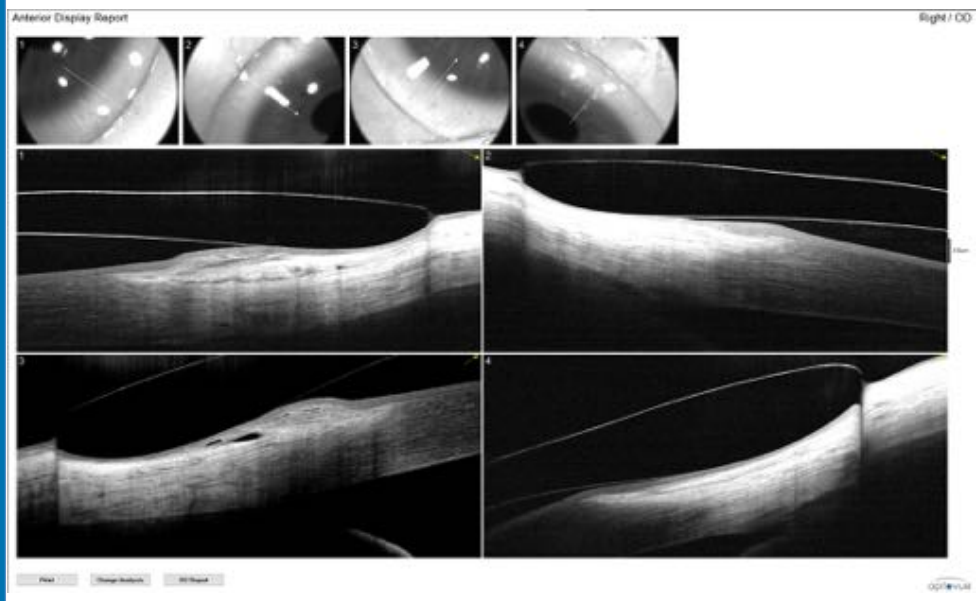

linsen centrum

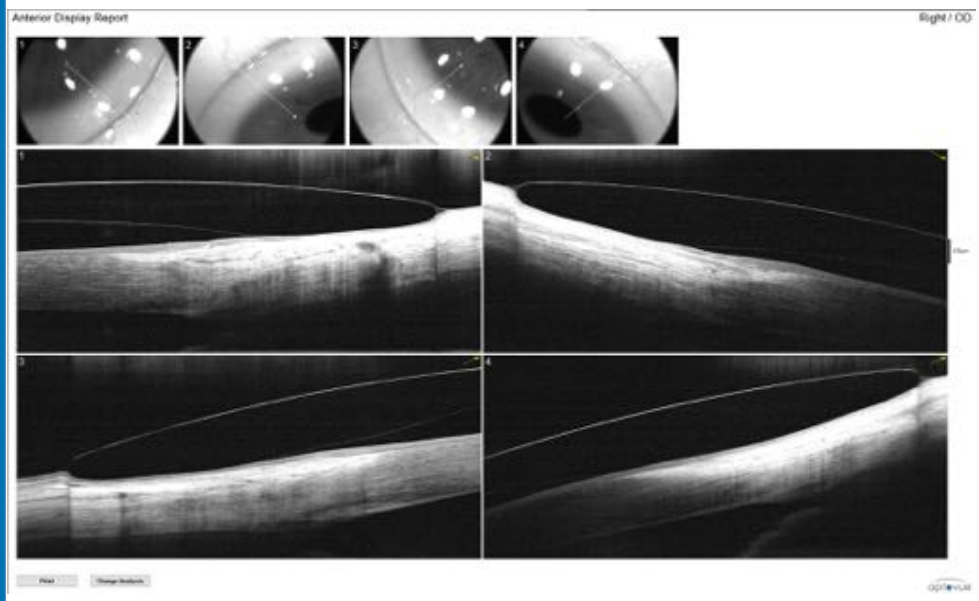

linsen centrum

Limbalzone steil

linsen centrum

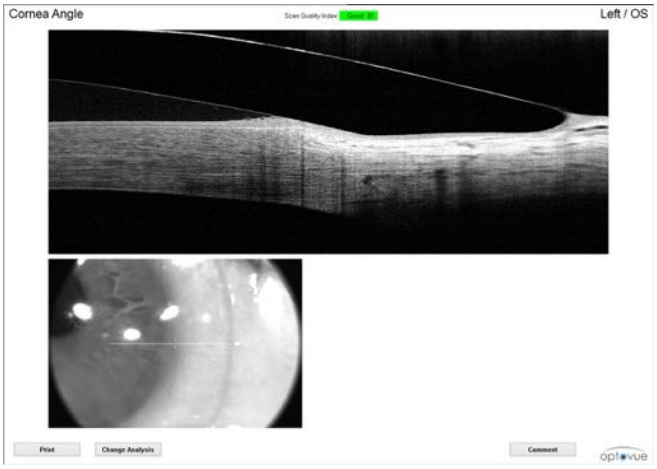

Microzysten

Limbalzone steil

linsen centrum

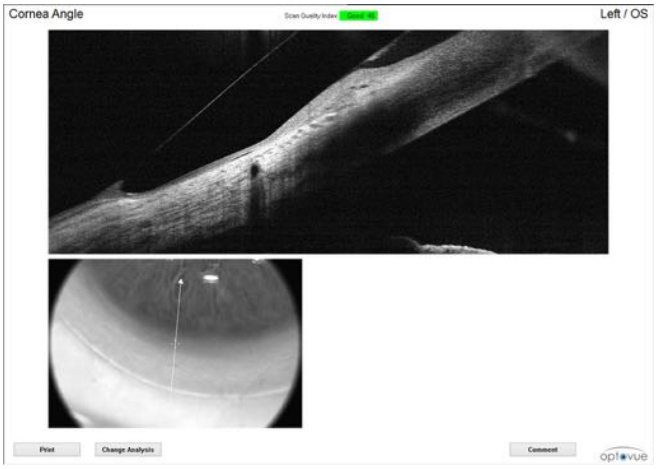

Ödeme

Limbalzone steil

linsen centrum

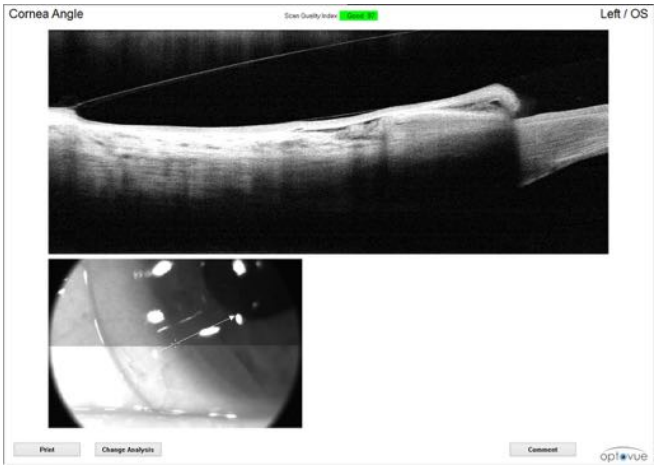

Bindehautprolabs

Ø-Skleral eher gross

linsen centrum

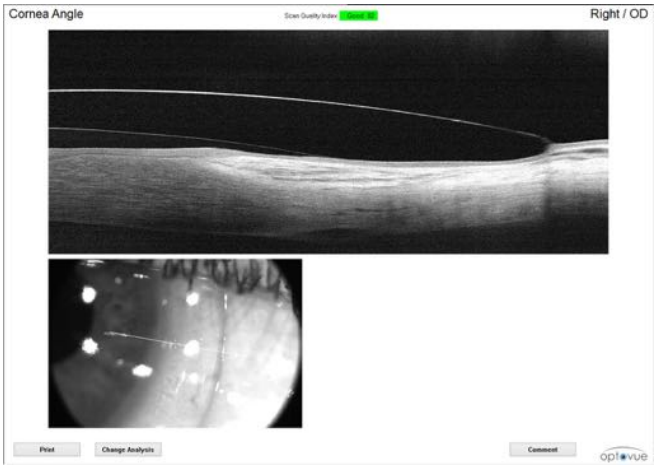

Limbal flach

linsen centrum

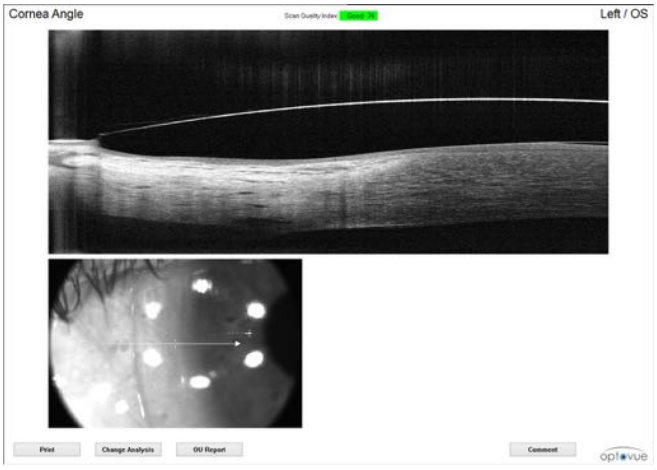

Limbal- und Skleralzone optimal

linsen centrum

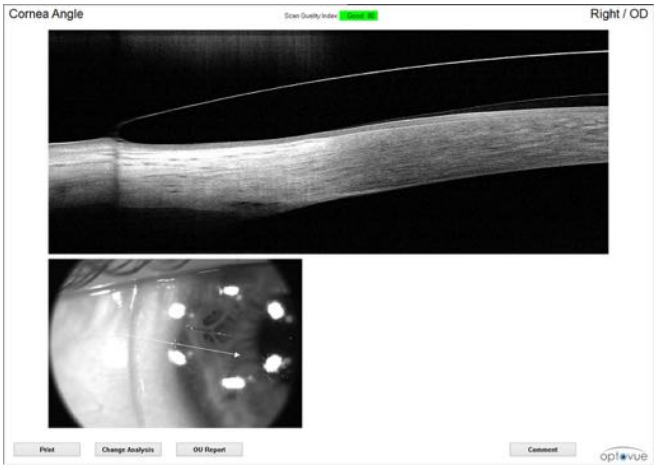

- Weiche Übergänge
- Sklera sanfte Auflage
- Limbal minimal clearance

Skleralradius im St HS zu flach

linsen centrum

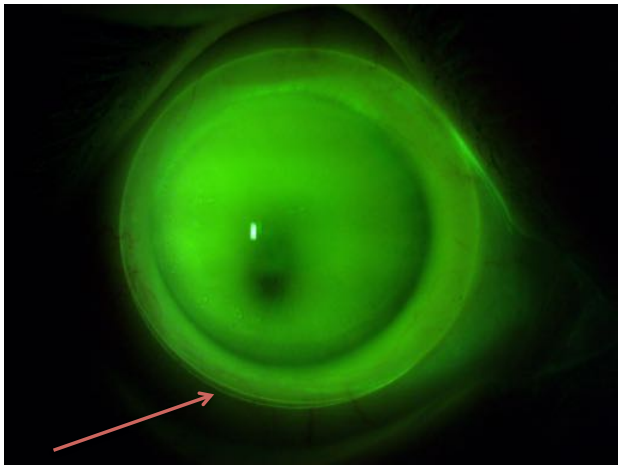

IST: Limbal und Skleraltorischen Linse (SMT -16/-17)

Im steilen HS ist der Skleralradius zu flach →

➔ Skleraltorus steiler (SMT -17/-39)

Skleralradius im St HS zu flach

linsen centrum

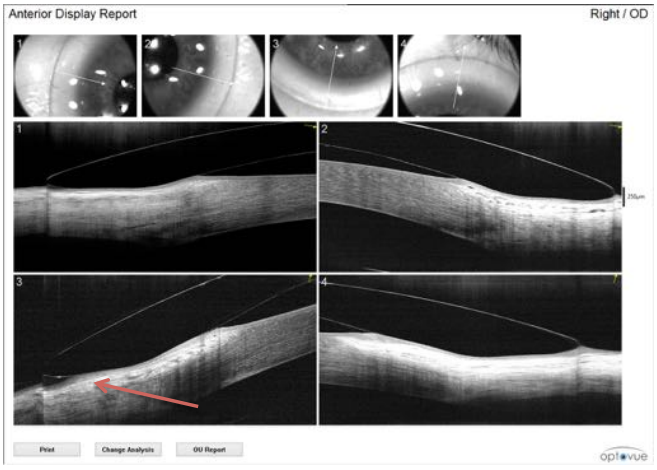

IST: Limbal und Skleraltorischen Linse (SMT -16/-17)

Im steilen HS ist der Skleralradius zu flach →

➔ Skleraltorus steiler (SMT -17/-39)

Skleralradius im St HS zu flach

linsen centrum

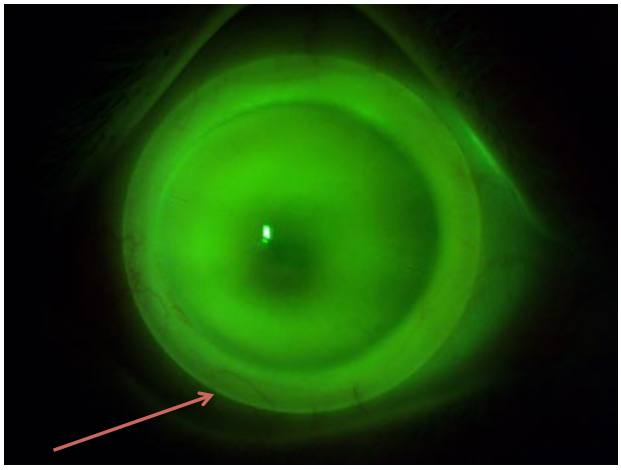

→ SMT -17/-39

Skleralradius im St HS zu flach

linsen centrum

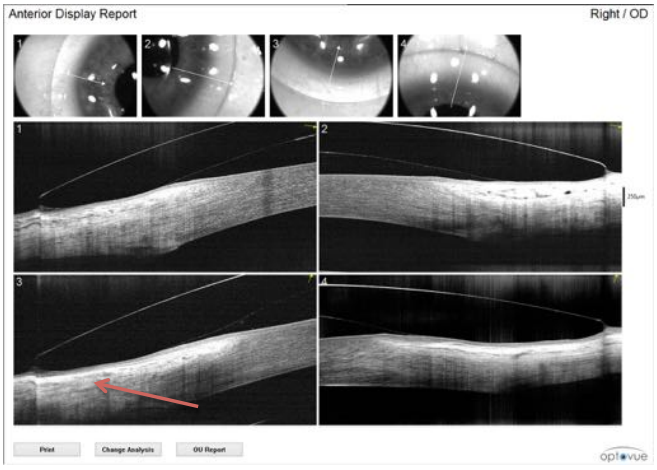

→ SMT -17/-39

Limbal zu viel Überbrückung

linsen centrum

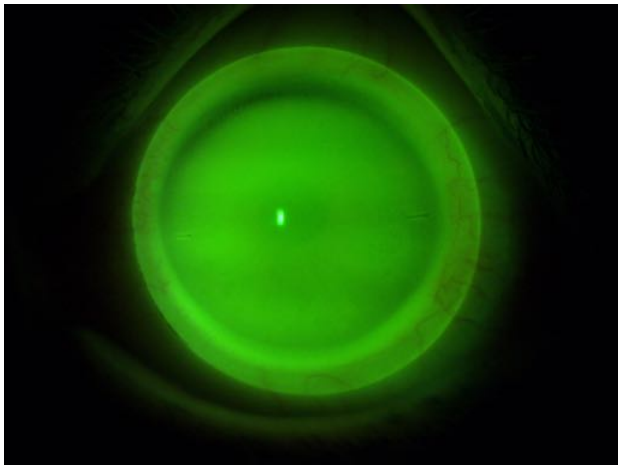

SMT -15/-26 Øskl 13.00mm

Zentral ideale Überbrückung bei Keratokonus

Limbal zu viel Überbrückung

linsen centrum

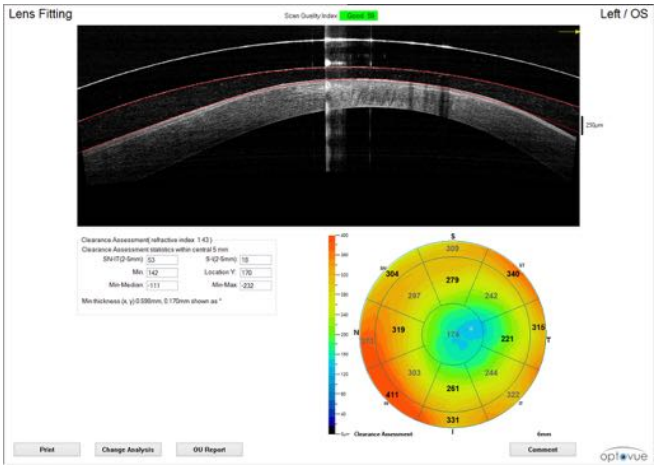

SMT -15/-26 Øskl 13.00mm

Zentral ideale Überbrückung bei Keratokonus nach einsetzen

Limbal zu viel Überbrückung

linsen centrum

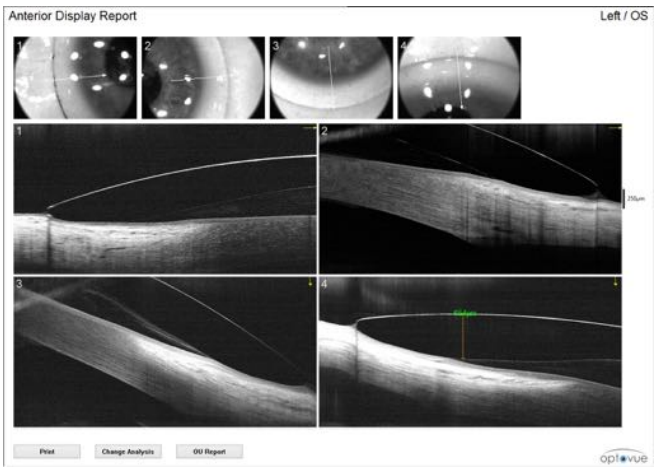

SMT -15/-26 Øskl 13.00mm

→ Änderung:

→Limbal flacher und
Ø Landingzone kleiner
(SMT -17/-28 Ø12.80mm)

Sagitaltiefe veringert sich!!!

CSO MS-39 Sklerallinsen Tool

linsen centrum

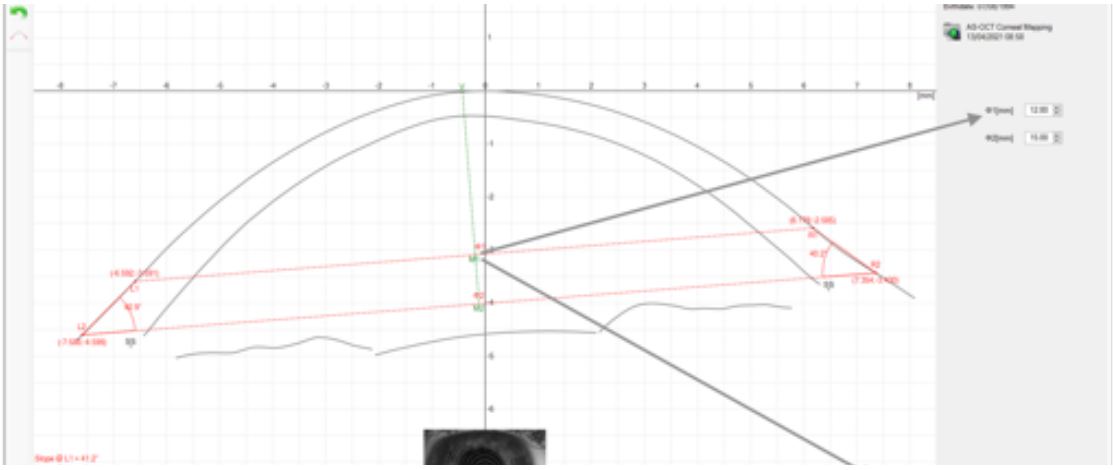

Bild: Elza Institute

CSO MS-39 für Sklerallinsen ANP

linsen centrum

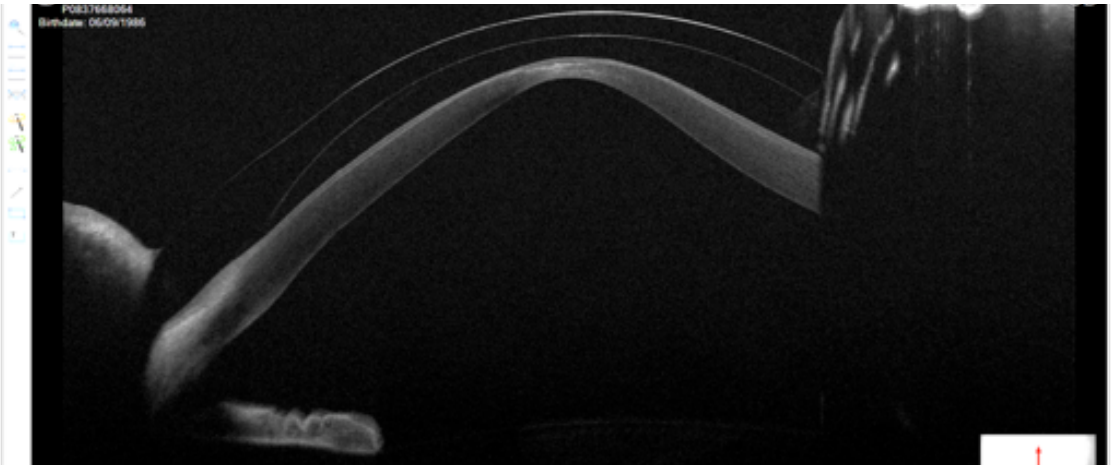

Bild: Elza Institute

CSO MS-39 für Sklerallinsen ANP

linsen centrum

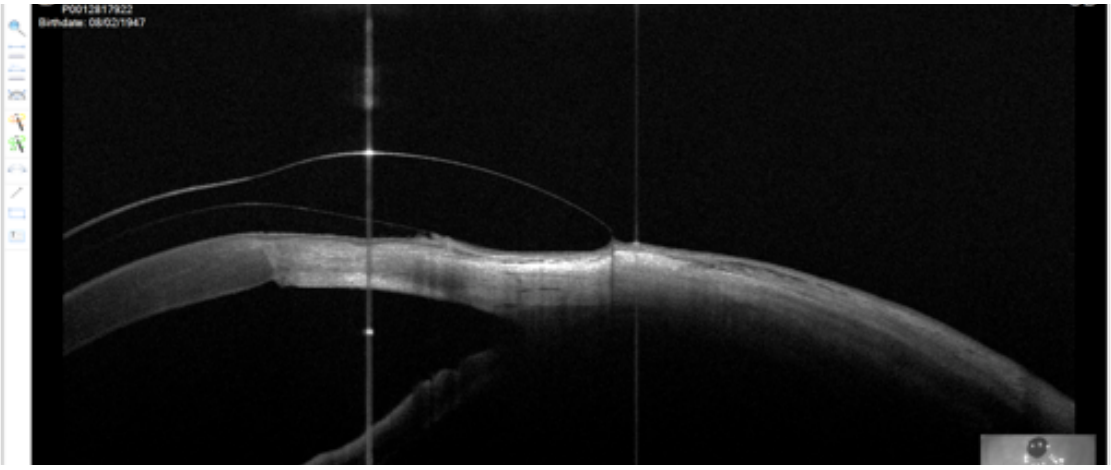

Bild: Elza Institute

CSO MS-39 für Sklerallinsen ANP

linsen centrum

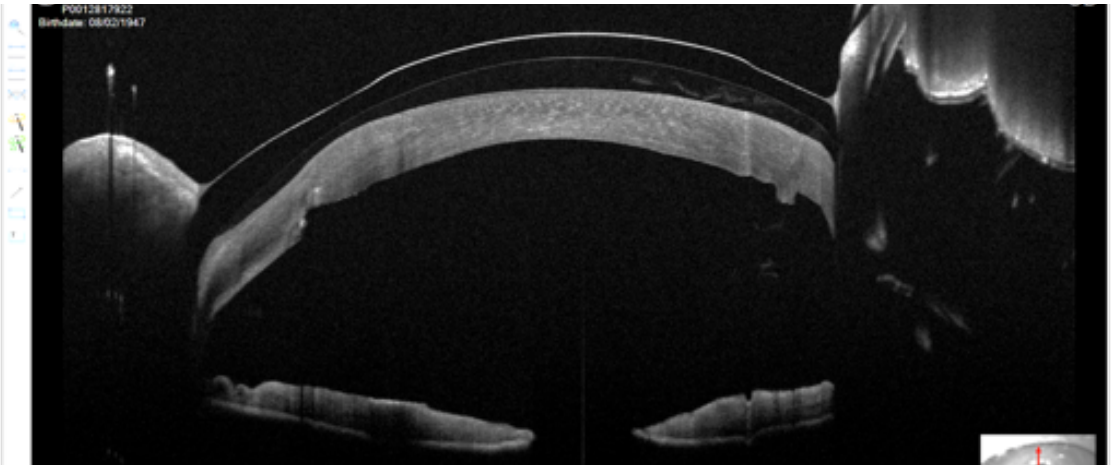

Bild: Elza Institute

CSO MS-39 für Sklerallinsen ANP

linsen centrum

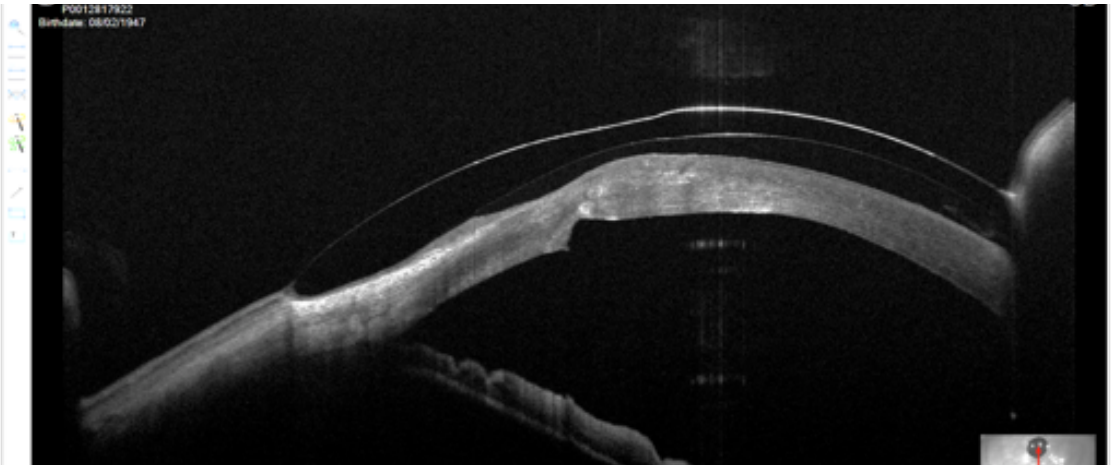

Bild: Elza Institute

Weitere Anwendungen AS-OCT

linsen centrum

- Dokumentation Post-Keratoplastik
- Dokumentation Narben und anderen Anormalitäten…
- Ortho-Keratologie
  - Epithelial Thickeness
  - Stromal Thickness and Changes
- Rand-Profil Weichlinsen und formstabilen Linsen
- Hybrid-Linsen

Interface fluid Syndrome IFS

linsen centrum

- Zustand nach LASIK, Fuchsdystrophie, DSAEK
- IFS nach Sklerallinsen tragen mit DK/t 200 & minimales Postlens Reservoir von 30-40 Micron



Figure 1 Interface fluid on slit lamp examination **Figure 2** Interface fluid collection on anterior segment OCT

INTERFACE FLUID SYNDROME INDUCED BY SCLERAL CONTACT LENS

Authors Isabelle Müller, MD[1], Markus Ritzmann, MSc[2], Philipp B. Bänninger, MD[1]

Affiliations 1 Department of Ophthalmology, Cantonal Hospital of Lucerne, CH-6000 Lucerne-16, Switzerland
2 Falco Linsen AG, CH-8274 Tägerwilen, Switzerland

BACKGROUND

Interface fluid syndrome (IFS) describes the collection of fluid posterior to the Laser In Situ Keratomileusis (LASIK) flap. IFS has been described in patients after LASIK with elevated intraocular pressure, mostly induced by topical steroid therapy. IFS has also been reported in patients with endothelial decompensation due to Fuchs Endothelial Dystrophy (FED).

CASE DESCRIPTION

A 50-year old patient underwent a bilateral LASIK for high myopia in 2010. Due to FED with corneal decompensation, Descemet's Stripping Automated Endothelial Keratoplasty (DSAEK) was performed on his left eye in 2017 after previous uncomplicated cataract surgery. Due to irregular astigmatism, mini scleral contact lenses (SCL) were fitted six months after DSAEK in order to optimize visual correction from best-spectacle corrected visual acuity of 0.5 (Snellen chart) to best-contact lens corrected visual acuity of 1.0. After wearing the scleral lenses for more than eight hours, the patient observed halos and blurred vison after SCL removal. On examination there was a fluid collection in the interface posterior to the LASIK flap, which was also visible on the anterior segment OCT. After removal of the scleral lenses, the symptoms resolved spontaneously after two to three hours.

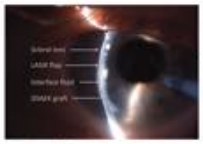

Figure 1 Interface fluid on slit lamp examination **Figure 2** Interface fluid collection on anterior segment OCT

linsen centrum

Post-Graft

linsen centrum

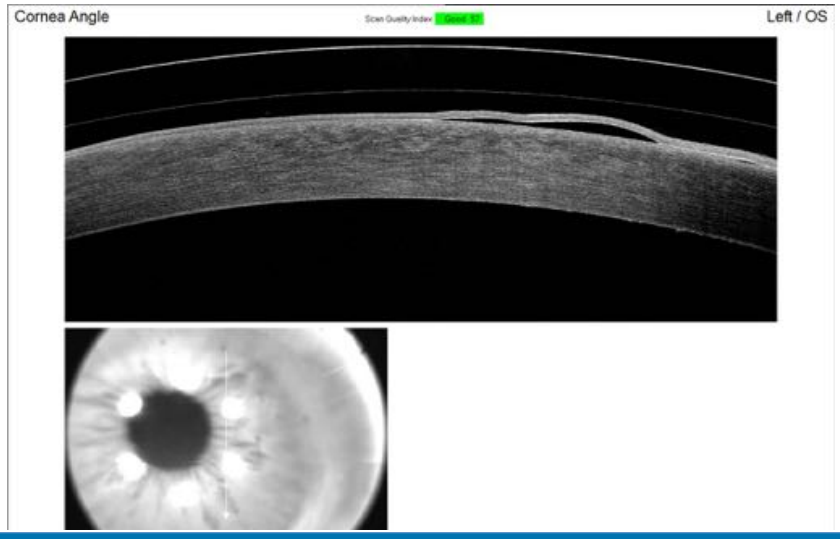

Scar-Tissue depth & location

linsen centrum

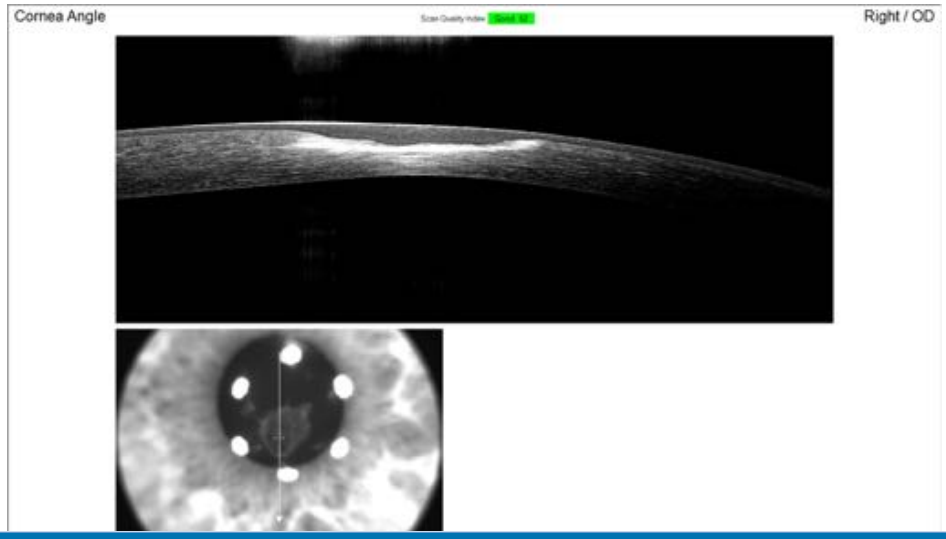

Filteringblebs

linsen centrum

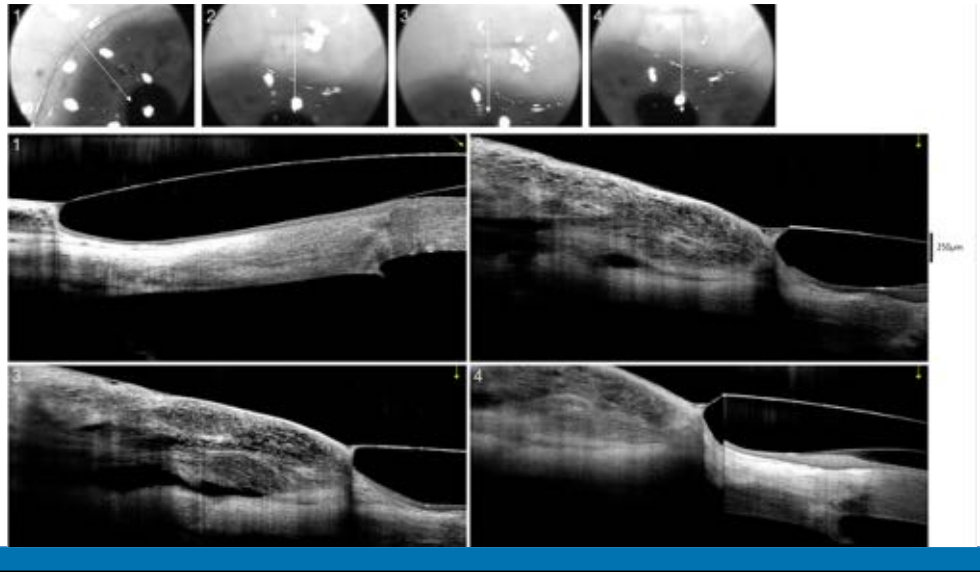

Filteringblebs

linsen centrum

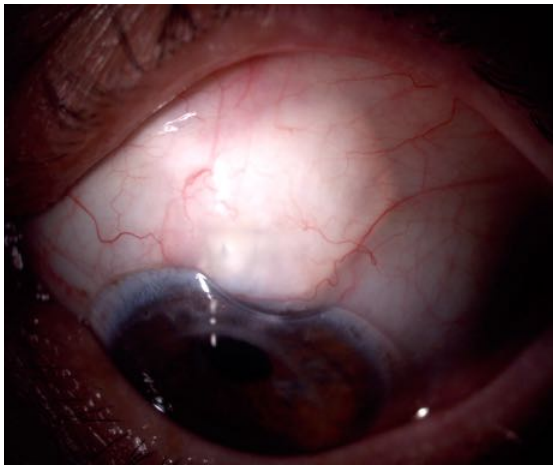

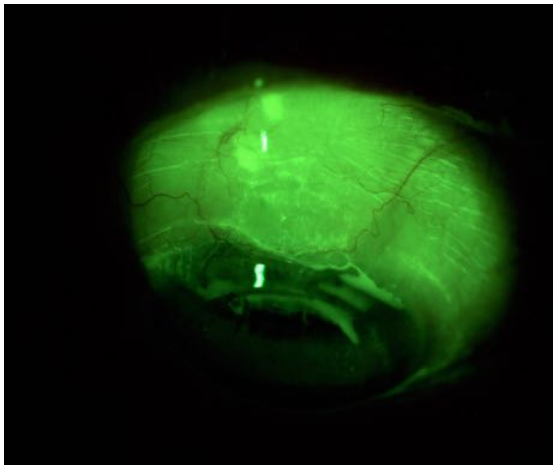

Achmed Tube

linsen centrum

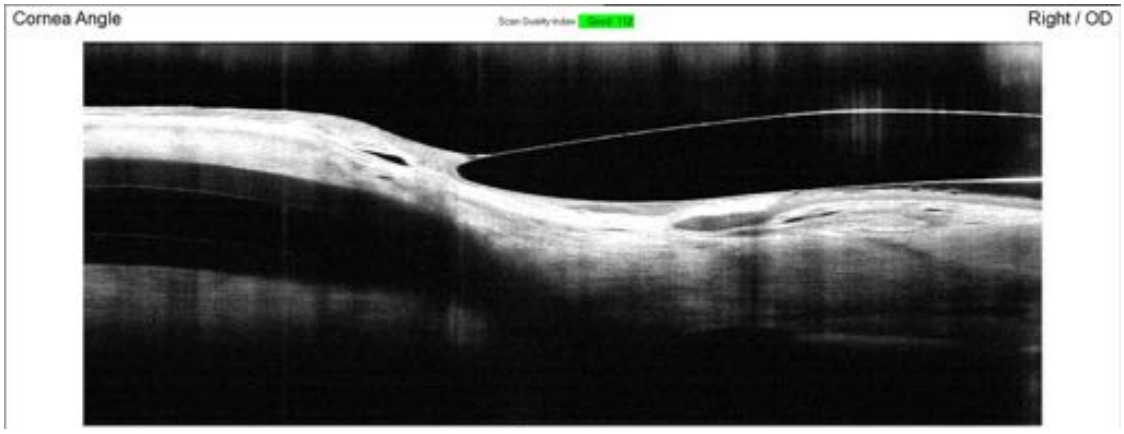

Achmed Tube

linsen centrum

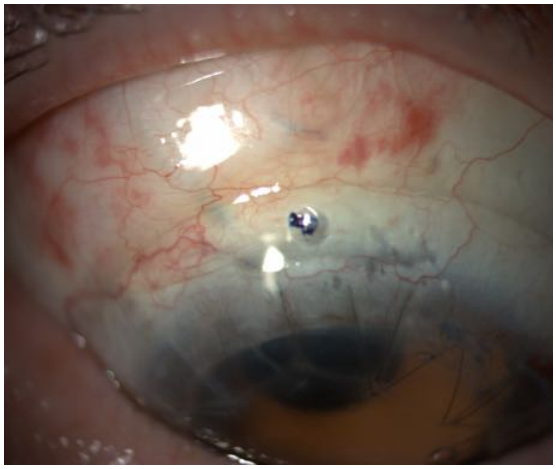

Pterygium

linsen centrum

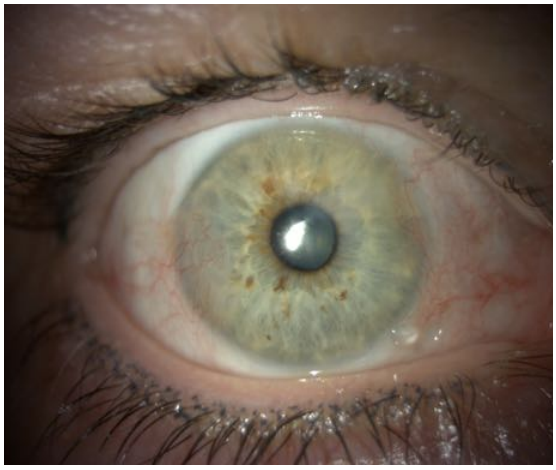

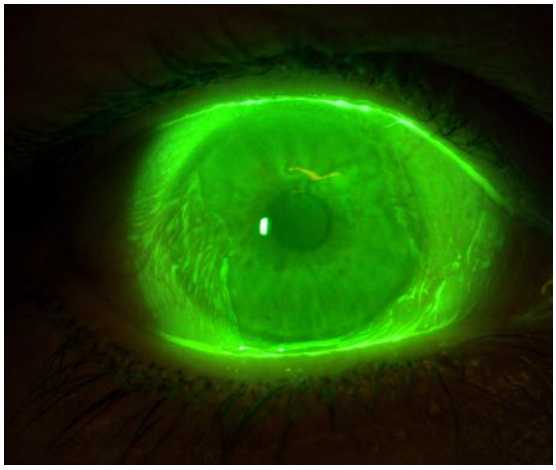

Pterygium

linsen centrum

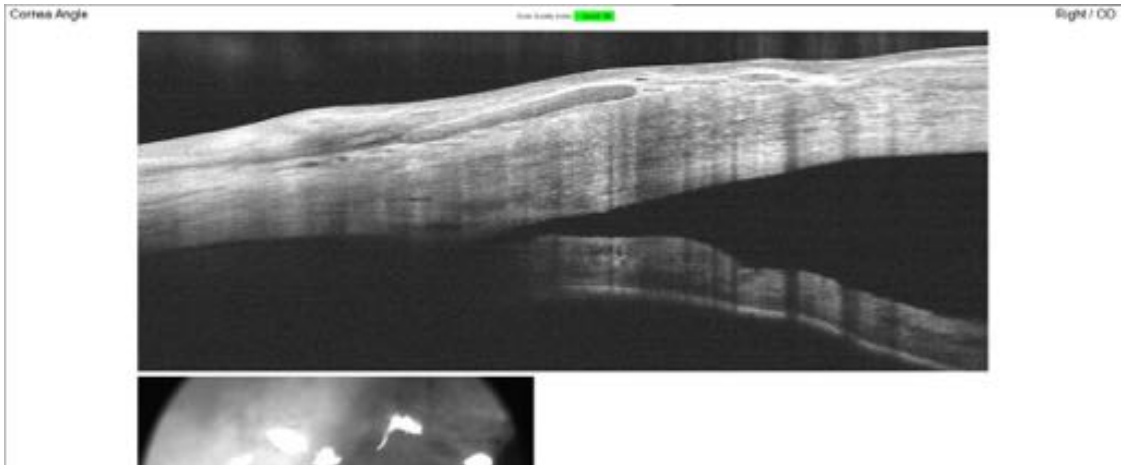

Pterygium

linsen centrum

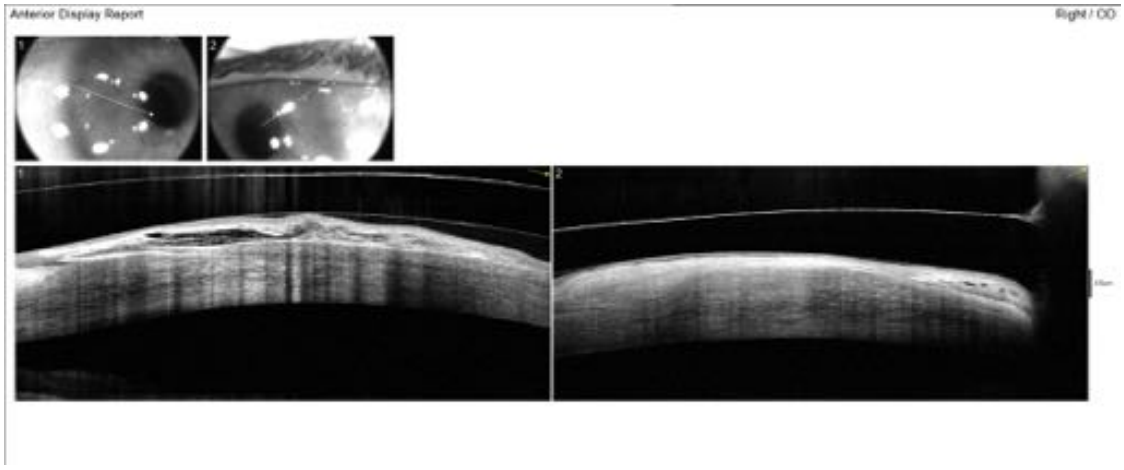

Pterygium

linsen centrum

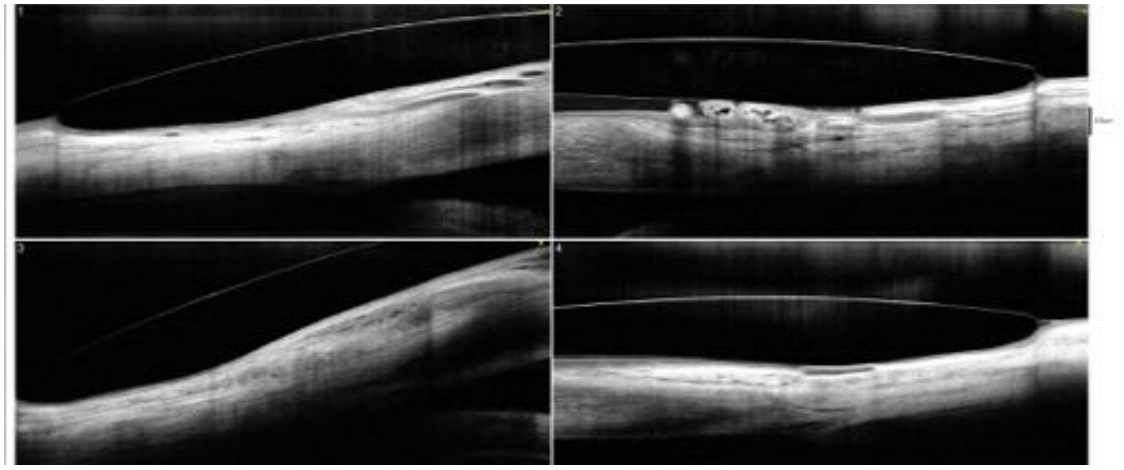

Pterygium

linsen centrum

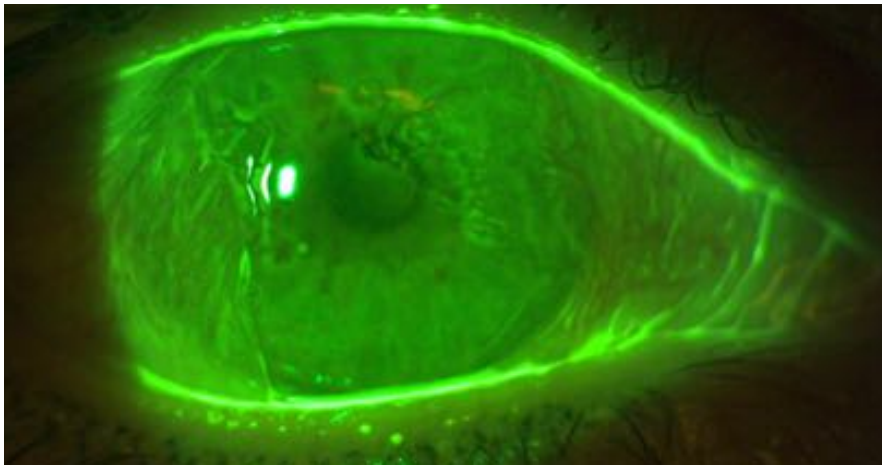

Weichlinsen Randprofil

linsen centrum

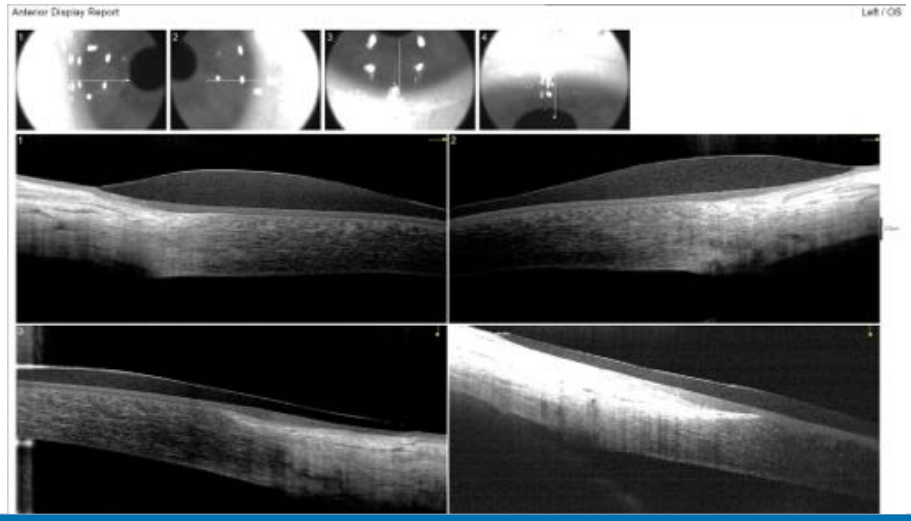

Oasys 1-Day

linsen centrum

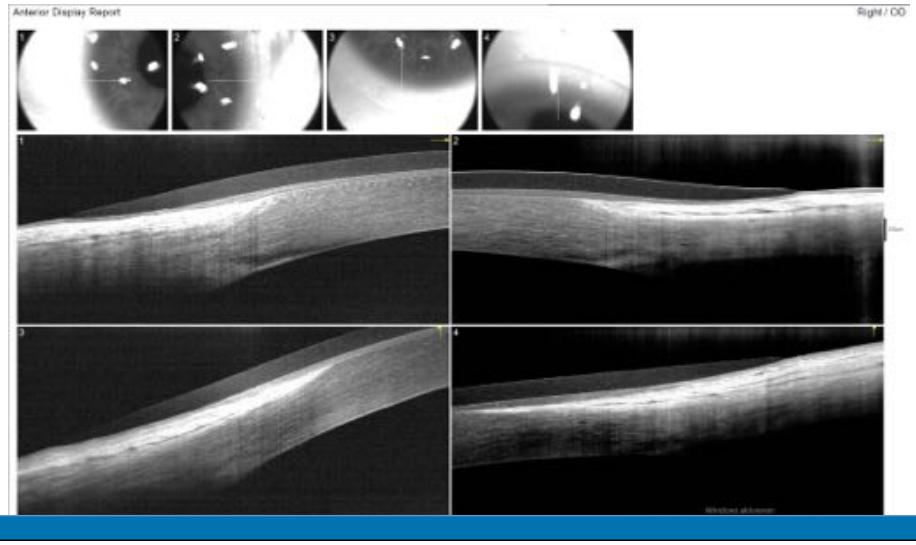

Hybridlinsen

linsen centrum

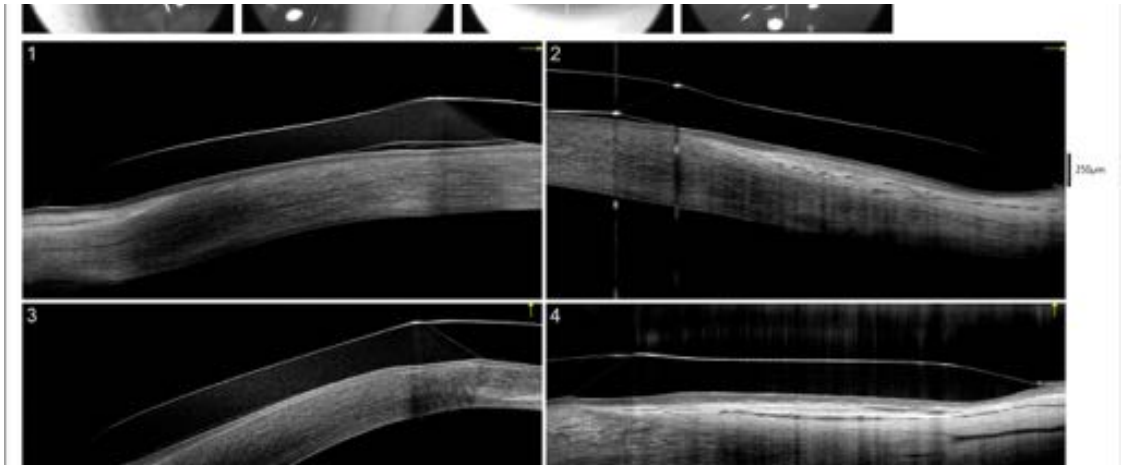

Formstabile Kontaktlinse FKQ

linsen centrum

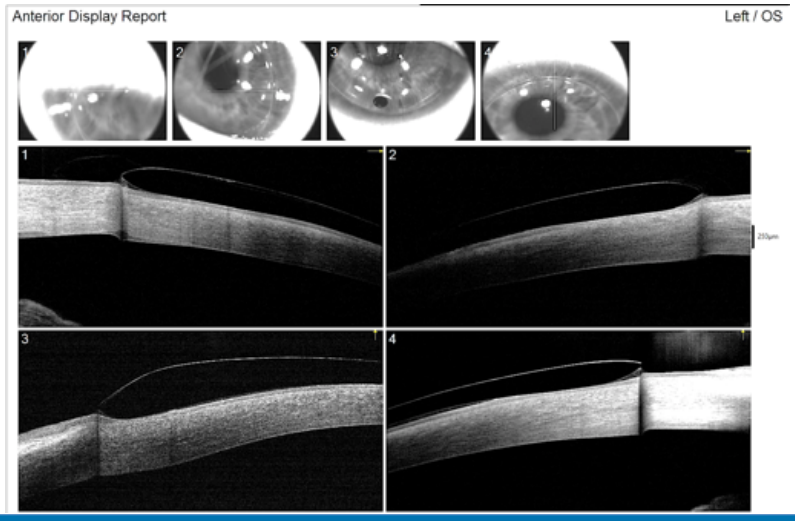

Formstabile Kontaktlinse FKQ

linsen centrum

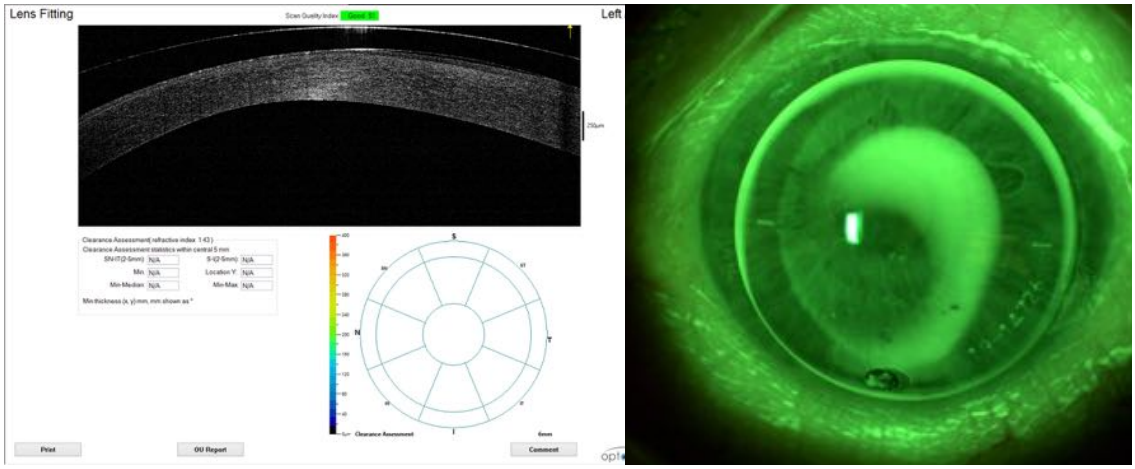

Corneoskleral Linsen

linsen centrum

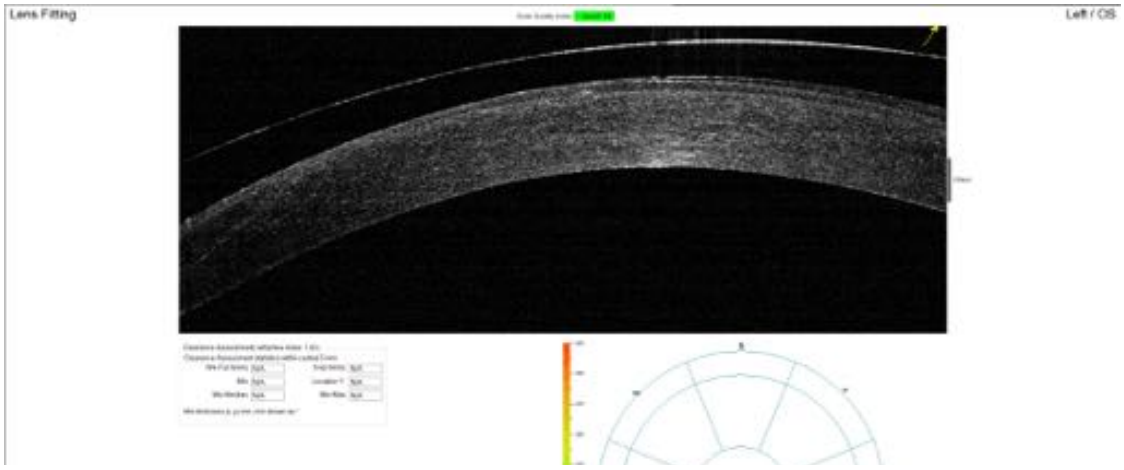

Corneoskleral Linsen

linsen centrum

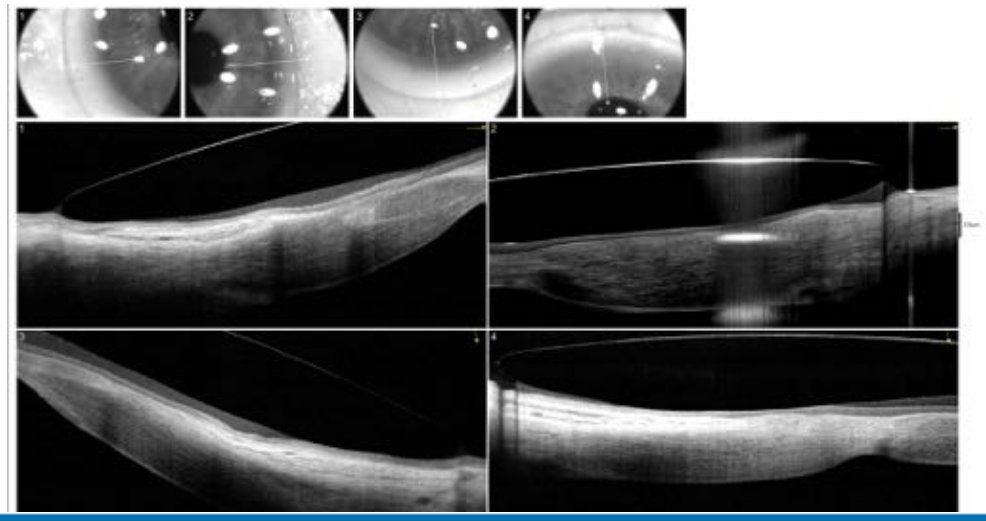

Corneoskleral Linsen

linsen centrum

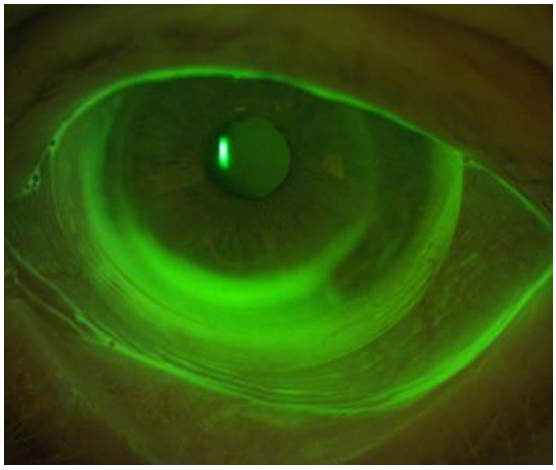

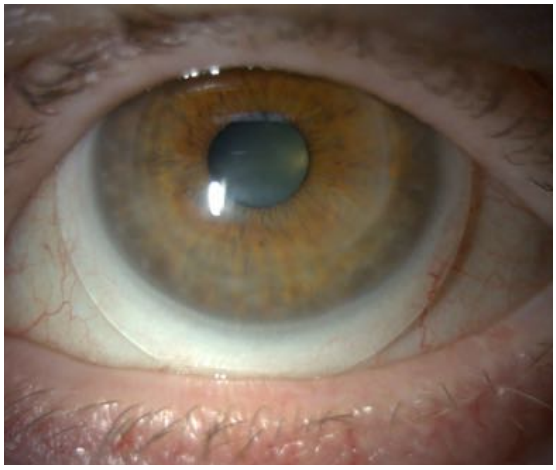

linsen centrum

Take Home

Take Home

linsen centrum

- AS-OCT ist eine wertvolle Ergänzung im optometrischen Alltag
  - Strukturen im anterioren Segment kennen und beurteilen
    - Kammerwinkel, Cornea, Sklera, Pachymetrie
- AS-OCT bringt die Sklerallinsen-Anpassung auf ein „tieferes“ Niveau ➔ weniger Überbrückung ☺
- Spaltlampe und angeeignete Skills sind weiter gefragt

linsen centrum

Kontakt:

Markus Ritzmann
Linsencentrum GmbH
052 551 10 80
mr@linsencentrum.ch
www.linsencentrum.ch
scleral.lenses@gmail.com